47th ANNUAL INTERNATIONAL CONGRESS
EHS 2025 JUNE 4-6 PARIS - FRANCE

Inguinal Hernia

Repair of Giant Inguinal Hernias (GIH) with Loss of Domain (LOD) using Botulinum Toxin A and the Madrid Repair Technique: a Case Report

Federico Biolchini MD, FACS
Villa Verde private hospital, Reggio Emilia, Italy

CASE REPORT

♂, 64 years old, Type II GIH (40 years lasting) with LOD, concurrent renal cistic neoplasm (Bosniak III)

Comorbidity: arterial hypertension; mild obesity

TREATMENT

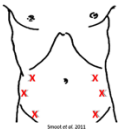

Smoot et al. 2011

60 days

Botox 300 UI/20 mm saline
6 point injection under ultrasound
1 ml/each of 3 lateral muscle

Sac isolation

Hernia reduction

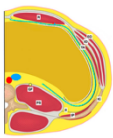

Reverse TAR and Madrid reconstruction (BIOA + polypropilene mesh)

Munoz-Rodriguez JM, et al Reverse TAR may be added when necessary in open preperitoneal repair of lateral incisional hernias: a retrospective multicentric cohort study. Surg Endosc. 2022 Dec;36(12):9072-9091.

6 hour OR (including partial nephrectomy)
End IA pressure + 3mmHg
Immediate extubation
No ICU
Complications: FA
Hospital stay: 7 days

No recurrence
12 months FU

GIH

Siriraj classification system for giant inguinal hernia

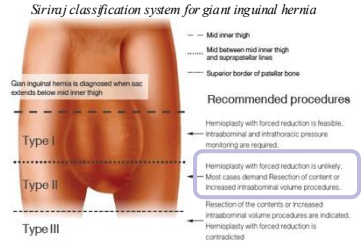

Table 1 Comparison of different surgical approaches to giant inguinoscrotal hernia

Bowel preparation	Pneumoperitoneum	Laparoscopic approach	Open abdominal approach	Extended inguinal approach	Orchiectomy	Bowel resection	Orchiectomy	Scrotum resection	Components separation	Mesh in premuscular position
-	+	+	+	+	+	-	+	-	+	+
-	-	+	+	+	2x	-	1	-	+	+
+	-	+	+	+	-	+	+	+	-	-
+	-	+	+	+	-	+	+	+	-	-
+	-	+	+	+	-	+	+	+	-	-