

Surgical approach of a recurrent parastomal hernia with loss of domain

VEJARANO Lindsay, Castillo Giancarlo, Condor Jose
 Luis Negreiros Vega Hospital/ESSALUD-Lima (Perú)

Aim

To describe our surgical treatment in a patient with recurrent paraostomal hernia and loss of domain in a peruvian complex abdominal wall unit.

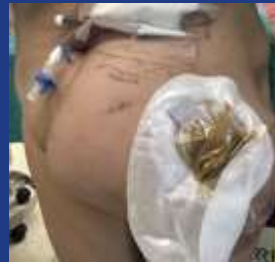Material & Methods

A 56-year-old female patient with a history of rectal cancer treated with abdominoperineal resection in 2011 developed a parastomal hernia. In 2017, a primary fascial repair was performed, which subsequently recurred. The patient underwent reoperation in 2019, retromuscular mesh was placed. 4 years later, she came to our hospital with parastomal hernia type IV. A Valsalva computed tomography scan was performed, revealing a defect size 6.5 centimeters and a hernia sac measuring 24x20x13.5 centimeters. The tanaka index was calculated to be 44%. Prehabilitation was conducted using preoperative progressive pneumoperitoneum 3 weeks before surgical day.

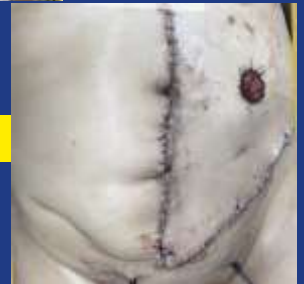Results

A modified retromuscular sugarbaker repair (pauli's technique) was performed. Following laparotomy, the pneumoperitoneum facilitated the release of adhesions between the intestines and the hernia sac. Subsequently, retromuscular dissection was carried out, left transverse abdominal release and a 30x30centimeters polypropylene mesh was placed, also repairing associated epigastric and inguinal hernias. The stoma was lateralized within the retromuscular space and drains were placed. The patient was discharged on the 6th postoperative day without complications. After 18 months of follow up, no recurrence was observed.

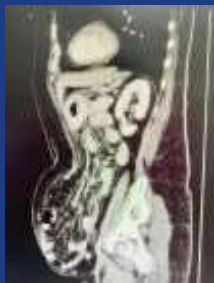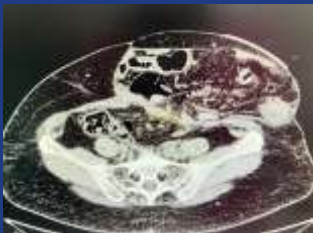Before



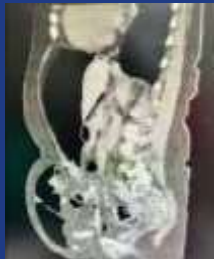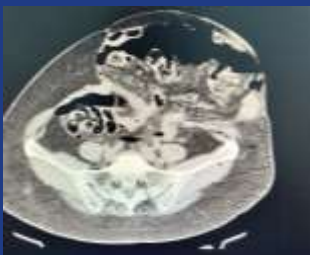
After



Prehabilitation CTscan



Posthabilitation CTscan



Conclusions

Despite the different surgical repair options, parastomal hernias remain a challenge. Preoperative progressive pneumoperitoneum facilitates the gradual increase of pressures and expansion of the abdominal cavity volume. In our patient, prehabilitation with the described surgical approach was crucial to achieve favorable results.

References

1. Pauli EM, Juza RM, Winder JS. How I do it: novel parastomal herniorrhaphy utilizing transversus abdominis release. *Hernia J Hernias Abdom Wall Surg.* August 2016;20(4):547-52.
2. Śmietański M, Szczepkowski M, Alexandre JA, Berger D, Bury K, Conze J, et al. European Hernia Society classification of parastomal hernias. *Hernia J Hernias Abdom Wall Surg.* February 2014;18(1):1-6.
3. Gavigan T, Rozario N, Matthews B, Reinke C. Trends in parastomal hernia repair in the United States: a 14-y review. *J Surg Res.* October 2017;218:78-85.
4. Gil G, Szczepkowski M. A new classification of parastomal hernias--from the experience at Bielański Hospital in Warsaw. *Pol Przegl Chir.* August 2011;83(8):430-7.
5. Rendell VR, Pauli EM. Parastomal Hernia Repair. *Surg Clin North Am.* October 2023;103(5):993-1010.