

## Open Retromuscular Approach for Large Lumbar Incisional Hernia. A Clinical Case Report

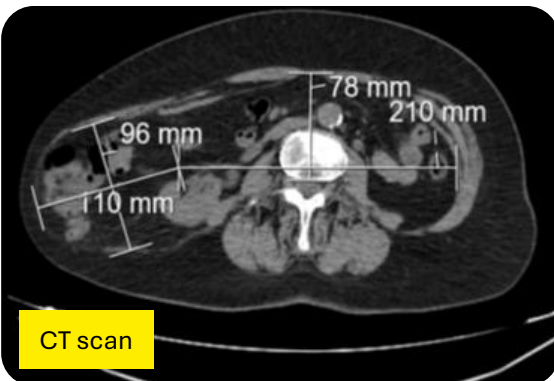
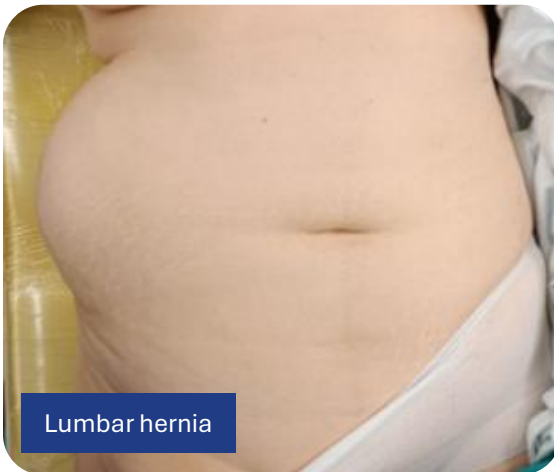Ricardo SOUTO<sup>1</sup>, Joana Figueiredo<sup>1</sup>, Miguel Carracha<sup>2</sup>, Alexandra Cabeleira<sup>2</sup>

<sup>1</sup> Hospital Garcia de Orta, Almada, Portugal

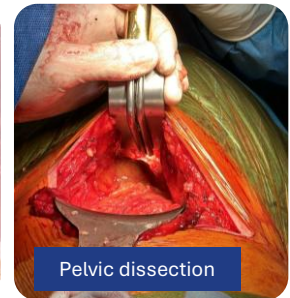
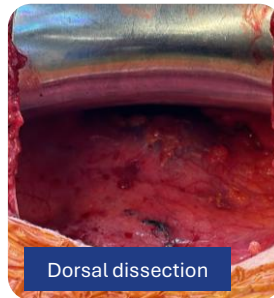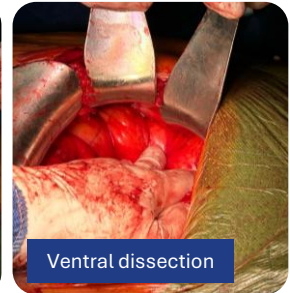
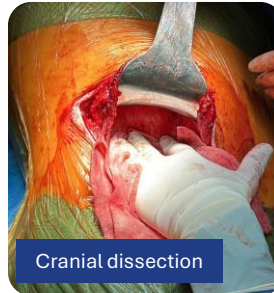<sup>2</sup> Hospital de Cascais Dr. José de Almeida, Portugal

**Introduction:** Lumbar incisional hernias continue to pose considerable surgical challenges, with no universally accepted best approach.

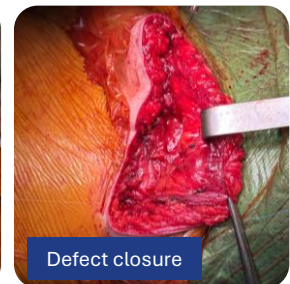
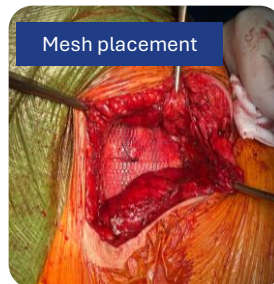
**Clinical case:** A 63-year-old woman was referred to our unit due to a large right lumbar bulge and discomfort that affected her quality of life. She had previously undergone an open right pyeloplasty. CT scan confirmed the presence of a large hernia with a defect measuring 10x11 cm and with a 15% loss of domain. An open lateral surgical approach was decided.



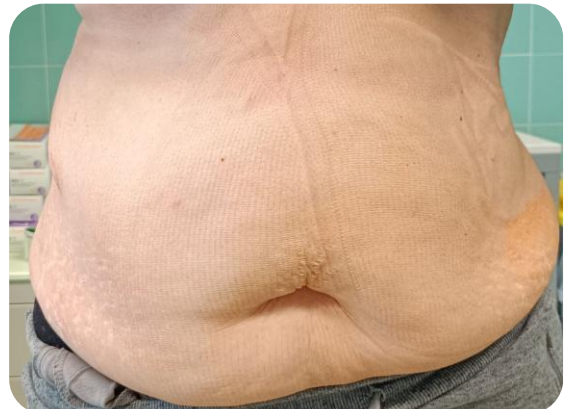An incision was made along the previous scar and a wide retromuscular extraperitoneal dissection was performed, ensuring an extended overlap for mesh reinforcement.



A medium-weight nonabsorbable macroporous synthetic mesh was implanted without fixation.



Postoperative period was uneventful. After 1 year of follow-up the patient remains symptom-free and without recurrence.



**Conclusions:** Although technically challenging, open lateral retromuscular repair with wide mesh overlap seems to be a valid option for lumbar incisional hernias and with good outcomes.