

"Prospective analysis of safety, efficacy, and outcomes of the minimally invasive eTEP technique for ventral hernias"

J. Trujillo-Díaz, J.R. Gómez-López, P. Concejo-Cutoli, A. Benitez-Riesco, F. Schenone, M.A. Montenegro, J.C. Martín Del Olmo.

Medina Del Campo Hospital - Valladolid (Spain)

AIM:

Ventral hernias are prevalent in general surgery, and minimally invasive approaches, such as laparoscopic enhanced-view totally extraperitoneal (eTEP) repair, have become increasingly preferred due to their reduced morbidity, lower postoperative pain, and faster recovery. This study aims to analyze the short- and long-term outcomes of patients undergoing laparoscopic eTEP repair at our Hospital over an average follow-up of 30 months.

MATERIAL & METHODS:

This prospective observational study included patients treated with laparoscopic eTEP for primary or secondary ventral hernias from August 2021 to April 2025. Data on demographics, comorbidities, hernia characteristics, surgical approach, and postoperative outcomes were collected and analyzed. Follow-up evaluations involved clinical and radiological assessments.

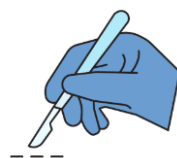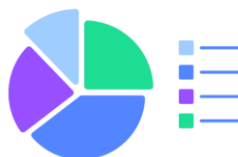RESULTS:

TOTAL	115 (100%)
Age	64 years (IQR: 43 – 73 years)
Postoperative hospital stay	1.4 ± 0.6 days (Range: 1 – 3 days)
BMI (kg/m ²)	30.6 ± 4.7 kg/m ²
Follow-up	569 days (IQR: 317 – 893) 18 months (IQR: 10 – 29)
Male / Female	♂ 63 (54.8%) / ♀ 52 (45.2%)

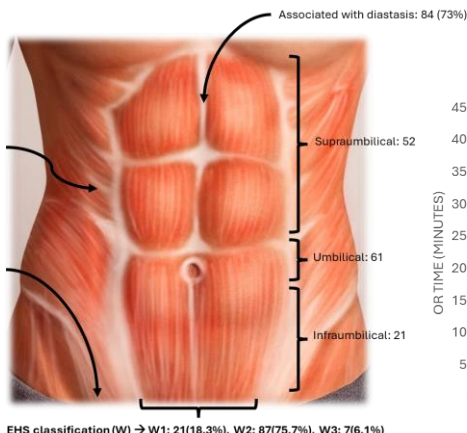
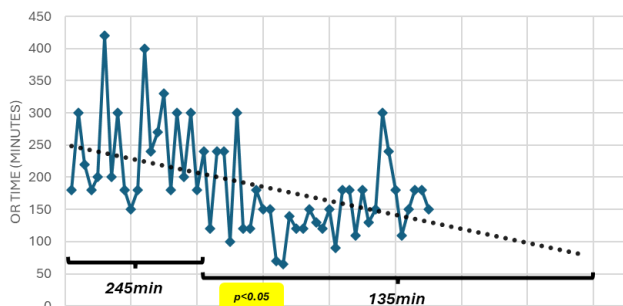
	N	%
Primary	28	24.3%
Incisional	87	75.7%
(Recurrent)	(31)	(35.6%)
Midline hernia	101	87.8%
Lateral hernia	14	12.2%
Associated with inguinal hernia	15	13%

	N	%
SURGICAL TECHNIQUE		
Rives-Stoppa	98	85.2%
Transversus abdominis muscle release (TAR)	17	14.8%
Unilateral TAR	10	8.7%
Bilateral TAR	7	6.1%
Cierre de vaina posterior de los rectos	86	74.8%
Nº of ports	4.2 ± 0.4	(3 – 5)
Preoperative botulinum toxin	29	25.2%

MORBI-MORTALITY	%
GLOBAL COMPLICATIONS	18.3%
Clinical seroma	13.9%
Acute urinary retention (AUR)	0.87%
Incarcerated hernia due to acute posterior rectus sheath dehiscence	0.87%
Haematoma	2.6%
MAJOR complications (Dindo-Clavien2III) (small bowel occlusion due to acute posterior rectus sheath dehiscence)	0.87%
INTRAOPERATIVE complications	
REINTERVENTION (acute posterior rectus sheath dehiscence → Laparoscopic Re-eTEP-TAR)	0.87%
Seromas (S. Morales-Conde et al. classification)	
0b (non-clinical, only US)	33%
I (clinical <1 month)	10.4%
IIa (Clinical 1-3 months)	3.5%
Haematoma (resolved after the 1st postoperative month without drainage or Re-IQ)	1.7%
Haematoma (resolved after the 3rd postoperative month with drainage)	0.87%
Surgical site infection (SSI)	0
Mesh infection	0
Recurrence	0
Mortality	0



OPERATIVE TIME



CONCLUSION:

- Laparoscopic eTEP repair for ventral hernias offers favourable short- and long-term outcomes, including low complication rates, no recurrences, and expedited recovery.
- These results confirm the safety and efficacy of eTEP for ventral hernia management, supporting its role in minimally invasive surgery.