

## "Posthabilitation": first published case of the botulinum toxin use after intervention

David Díaz Pérez, Javier Serrano González, Laura Colao García, Miguel Ángel Hernández Bartolomé, Ana Eloisa Pazos Crespo, Guadalupe Sevilla Santos, Pablo Galindo Jara

*Department of General & Digestive Surgery. University Hospital of Torrejón. Madrid. Spain*  
*Faculty of Medicine. Francisco de Vitoria University. Madrid. Spain*

### AIM

Evisceration is a rare complication that occurs when multiple risk factors coexist, with morbidity and mortality rates reaching concerning levels. Botulinum toxin (BT) has been described for prehabilitation but not for postoperative use. This study presents an urgent surgery for evisceration and the use of BT as "*posthabilitation*".

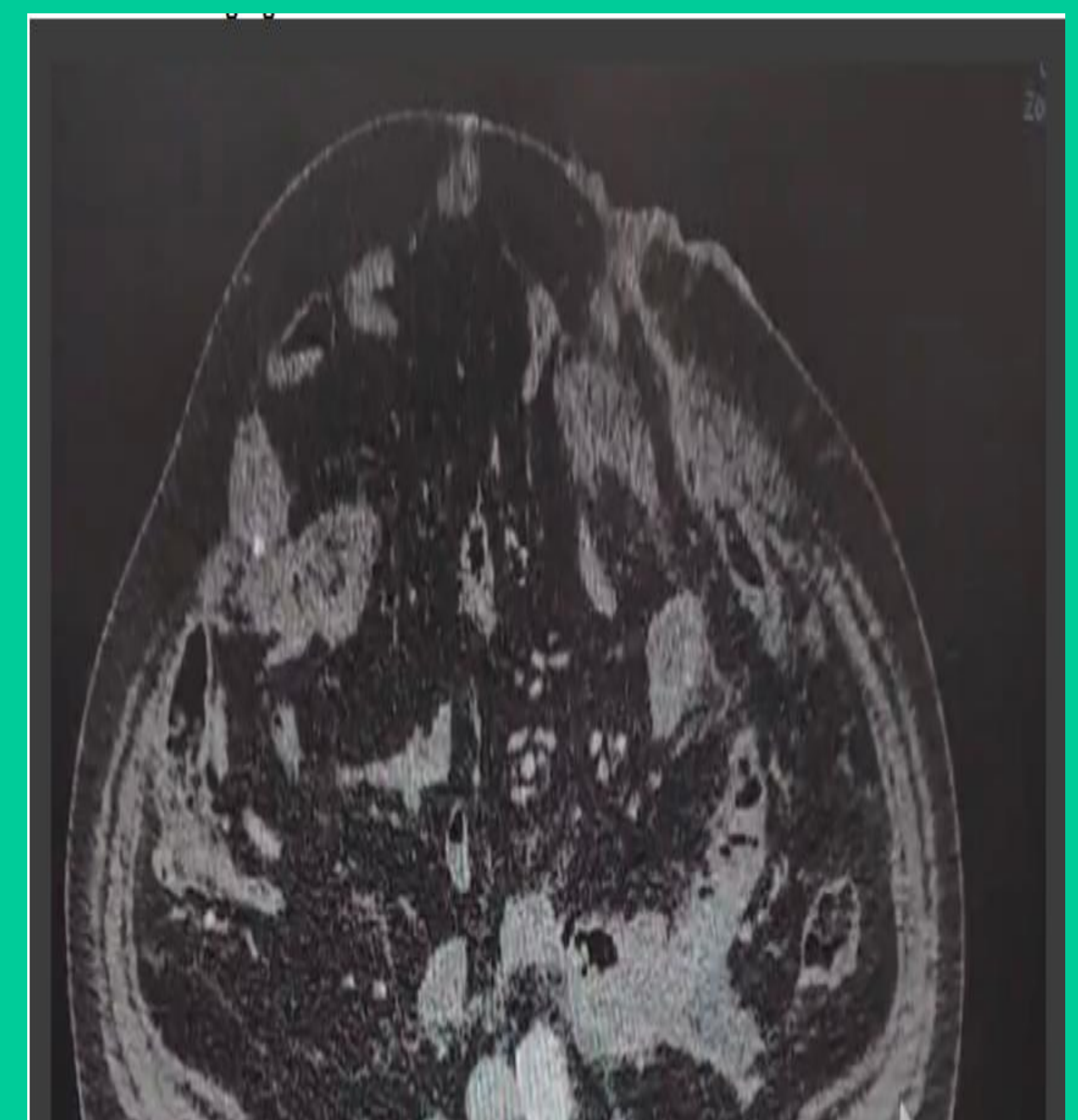


### MATERIAL&METHOD

Case and literature review

### RESULTS

A 78-year-old male with multiple comorbidities was transferred to our center following a Hartmann's procedure for acute diverticulitis and immediate evisceration, initially treated with primary suture. Within 24 hours, he developed respiratory failure and bowel obstruction. An urgent Rives eventroplasty was performed, requiring intensive care unit (ICU) admission. Approximately 12 hours postoperatively, BT was infiltrated into the abdominal wall to reduce the risk of further complications.



### DISCUSSION

Evisceration occurs in <1% of cases but has a morbidity rate of up to 77% and mortality reaching 45%. Type A BT has been reported as a therapeutic option to reduce tension in midline fascial closures, as it induces reversible denervation and paralysis of lateral musculature. Its use has been documented as prehabilitation for selected elective surgeries. In this case, it was used as postoperative rehabilitation in an emergency setting to improve surgical outcomes. This is the first published report of BT used in this manner.

### Conclusion

BT infiltration has been considered a chemical component separation technique with reversible and well-tolerated effects. Its prolonged action may facilitate postoperative abdominal adaptation to surgical changes. It could serve as a valuable tool for emergency surgeries and "posthabilitation".

