

Using Transillumination with Light to Demonstrate Eradication of Diastasis Rectus Abdominis during Robotic Surgery

Romilly K HAYWARD^{1,2}, Michael Brunner³, Oliver J Warren^{1,2}

¹Imperial College London, United Kingdom; ²Chelsea & Westminster Hospital NHS Fdn Trust,

³London North West University Healthcare NHS Trust - London (United Kingdom)

Background

- Robotic transabdominal retromuscular repair (TARM) offers an alternative approach to traditional open abdominoplasty for the management of postpartum diastasis rectus abdominis (DRAM).
- Here, we describe an innovative use of the Da Vinci robotic system's lightsource to transilluminate the DRAM, allowing precise visualisation of the defect before, during, and after repair, enabling accurate assessment of plication.

Method

- Following robotic docking, transillumination is utilised to highlight the DRAM as shown in Figure 1 (A).
- After entering the retrorectus space, the linea alba and its associated diastasis is plicated using a continuous inverting 'Geneva' stitch.
- Transillumination of the abdominal wall confirms reduction in the width of the DRAM as demonstrated in Figure 1 (B).
- Subsequently, the posterior layer is repaired with a continuous running suture, further plicating the diastasis and enhancing the 'waisting effect' of the repair.
- Transillumination is employed from inside the abdomen once more to confirm complete plication, as seen in Figure 1 (C).

Results

We successfully demonstrate the application of **transillumination** to confirm **intra-operatively**, eradication of DRAM during robotic surgery, employing a caudocranial TARM technique through three suprapubic ports.

This technique was also employed alongside robotic videos to **educate & reassure patients** by demonstrating DRAM eradication.

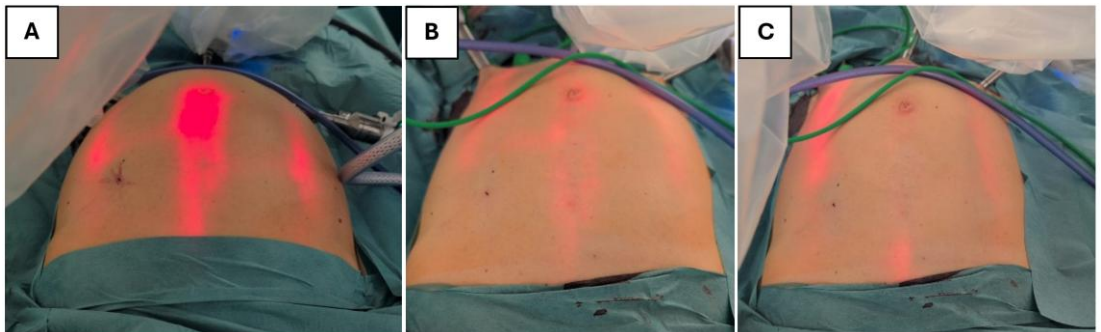


Figure 1: Transillumination of DRAM with robotic lightsource (A) prior to plication, (B) following 'Geneva' stitch repair of the diastasis, and (C) following closure of the posterior layer.

Conclusion

Transillumination with the robotic lightsource is an effective and practical technique for robotic repair of DRAM. This approach enhances visualisation of the abdominal wall defect, and provides accurate, real-time confirmation of successful plication.