47th ANNUAL INTERNATIONAL CONGRESS
EHS 2025 JUNE 4-6
PARIS - FRANCE

Parastomal hernia

Repair of Parastomal Hernias Using the Pauli Technique: A Series of 4 Cases

E.J. Villalobos Rubalcava MD FACS, **A. Hernandez Lopez** MD FACS FACG.
Centro Médico Abc - Ciudad De México (Mexico)

Aim

To share 4 cases of parastomal hernia repair, highlighting clinical outcomes and an average follow-up of 2 years.
The parastomal hernia repair poses a surgical challenge due to high recurrence rates and associated complications. The Pauli technique has emerged as an innovative and effective option, allowing better tension distribution and adequate posterior reinforcement of the defect.

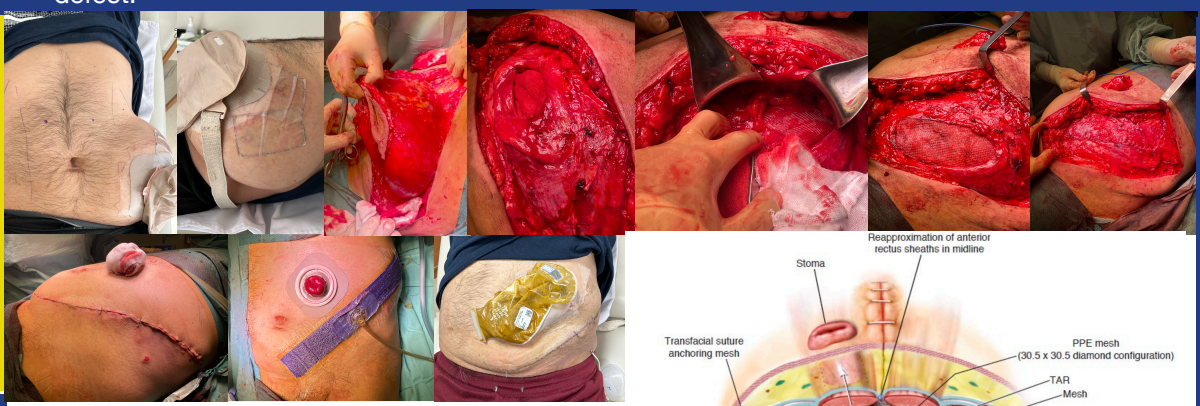

Material & Methods

4 patients with definitive parastomal hernia due to rectal cancer, who were repaired using the Pauli technique. The procedure included TAR release and creating an S-shaped pathway for the stoma loop to differentiate between the exit from the peritoneum and the aponeurotic exit, and placing a preperitoneal mesh.

Pauli Techinique summary

- Combine TAR with Sugarbaker
- Retromuscular mesh
- Uncut mesh, unmoved stoma
- Difficult to perform and configure correctly

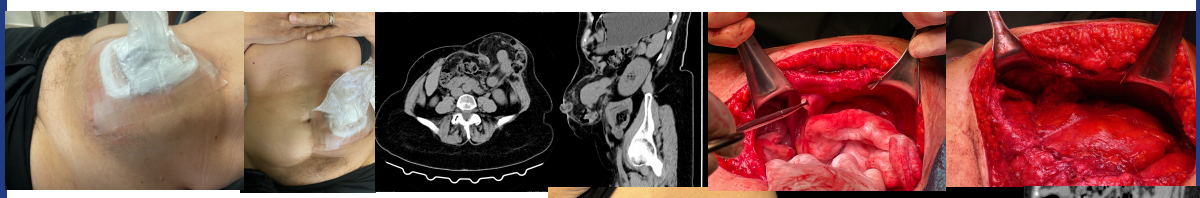

Results

No major postoperative complications were observed. All patients developed subcutaneous tissue seromas. One patient underwent preperitoneal collection, a drain was placed by radiology, carbapenem-sensitive Escherichia coli was cultured, we used macroporous synthetic meshes so after 12 days with ertapenem, the drain was removed and the patient progressed adequately.No recurrences were noted during follow-up. In a postoperative CT scan, a recurrence was initially suggested from the radiologist due to the preperitoneal stoma pathwaybut was later explained as part of the postoperative anatomy without significant complications, indicating the technique's high effectiveness.

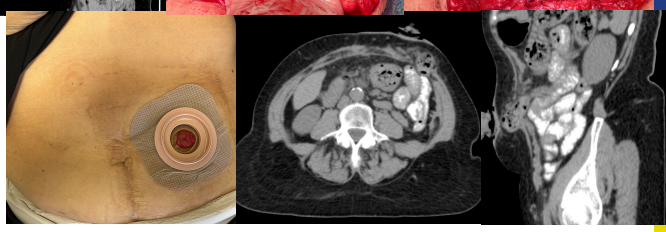

Conclusions

The Pauli technique for parastomal hernia repair proved to be effective and safe in this case series, with positive long-term outcomes. This technique offers a viable solution for managing complex parastomal hernias, improving patients' quality of life. It requires skill to calibrate the stoma through the peritoneum, leave the mesentery in contact with the mesh, exteriorize through the aponeurosis, and create an S-shaped stoma loop. Additionally, managing subocclusive events conservatively in the postoperative period is essential. Long-term follow-up for 2 years has shown its efficiency, emphasizing patient weight management.

Muysoms FE, Miserez M, Berrevoet F, Campanelli G, Champault GG, Chelala E, et al. Classification of primary and incisional abdominal wall hernias. Hernia. 2009 Jun;13(4):407-14. doi: 10.1007/s10029-009-0518-1.
Roth JS. Parastomal hernia repair: New techniques. Surg Technol Int. 2013;23:177-81.
Voeller GR, Sylvester N, Nassar M. Technique of retrorectus/retromuscular hernia repair. Surg Clin North Am. 2013 Oct;93(5):1091-107. doi: 10.1016/j.suc.2013.06.011.
Pauli EM, Belyansky I, Novitsky YW, Rosen MJ. Laparoscopic and robotic transversus abdominis release (TAR): A description of a novel technique and early outcomes. Surg Endosc. 2016 Nov;30(11):5209-14. doi: 10.1007/s00464-016-4883-2.
Kockerling F, Schug-Pass C, Berrevoet F, Bittner R, Chowbey P, Conze J, et al. Lap-TAR: A survey of the operative technique and early outcomes in 20 international hernia centers. Surg Endosc. 2019 Oct;33(10):3442-52. doi: 10.1007/s00464-019-06963-6.