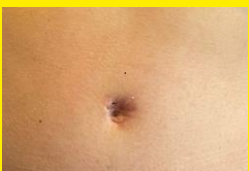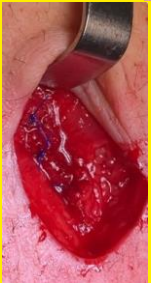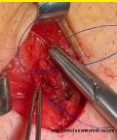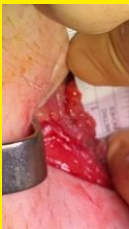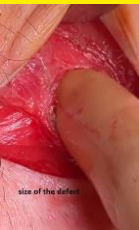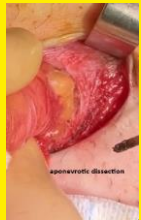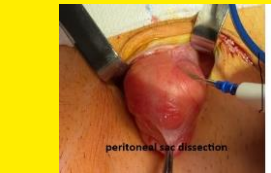


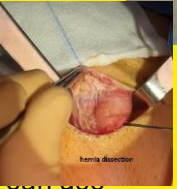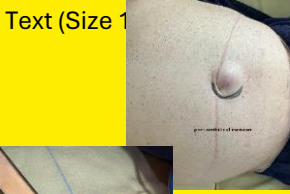SMALL anterior primary ventral hernia repair with stitches: is-it possible?

Dr JURCZAK FLORENT

Clinique mutualiste de l'estuaire Saint Nazaire France

Text (Size 1



personal local procedure with extractions of the French data base register (Club Hernie)
 Follow up with the assistance of a Clinical Research Associate

361 successive patients

procedure : general or sometimes local anesthesia , local incision , peritoneal sac dissection without resection ; aponevrotic dissection ; monobrin non or slow absorbable suture

Mean age 59,7 years (5 to 92 Y)
 149 women; 212 men
 average BMI 27,25 (11 to 46)

279 ombilical hernias
 (other alba or epigastric hernias)
 183 were <1 cm wide

Mean operative time **11 minutes** (6-30)

90 % ambulatory surgery; (1 day for other patients for medical considerations)

Pain managment (only Paracetamol) and one day compressive dressing

3 recurrences (< 1%) during the follow up (mean follow up: 4 years)

3 non absorbable suture removal on local anesthesia for skin irritation
No significant and no serious complication

local suture alone in small primary ventral hernias is
 a short term porcedure, easy to do , ambulatory
 procedure, without significant complication and low
 rate of recurrences