

GIANT DIASTASIS AND UMBILICAL HERNIA REPAIR WITH AUTOLOGOUS DERMIS GRAFT REINFORCEMENT

Aude LEHNEN¹, Jérôme MARTINEAU², Lucille NICHOLS², Jonathan DOUISSARD¹

¹ Visceral Surgery, University Hospital Geneva, Geneva, Switzerland

² Reconstr. and Plastic Surgery, University Hospital Geneva, Geneva, Switzerland

AIM

Reconstruction and reinforcement using artificial meshes is one of the preferred methods for large to very large the repair of rectus diastasis (RD) with umbilical hernia [1]. Using autologous de-epithelialized dermis as a reinforcement graft is an alternative to avoid implantation of synthetic material [2]. As this technique is not widely known, the essentials surgical steps are presented.

MATERIALS & METHODS

Technical note describing the surgical technique, illustrated by images from a typical case.

RESULTS

36-year-old patient suffering from a T1D3H1 RD postpartum in the M2 to M4 areas according to the EHS classifications [1] of 15 cm width resting and 25 cm width in Valsalva. After a standard abdominoplasty approach (Fig. 1A), a 30 x 15 cm abdominal dermis flap was de-epithelialized (Fig. 1B), resected (Fig. 1C) and defatted. A methylene blue de-epithelialization quality control (Fig. 1D) and final shaping of the graft was performed before placement in the sublay position following the Rives-Stoppa technique (Fig. 1E-G). The umbilicus could be reconstructed (Fig. 1H). On the 7th postoperative day, the patient was re-admitted to the operating theatre for necrosectomy and reconstruction of the neo-umbilicus. The rest of the postoperative course was uneventful. So far, no recurrence of hernia or diastasis at 90 days of follow up.

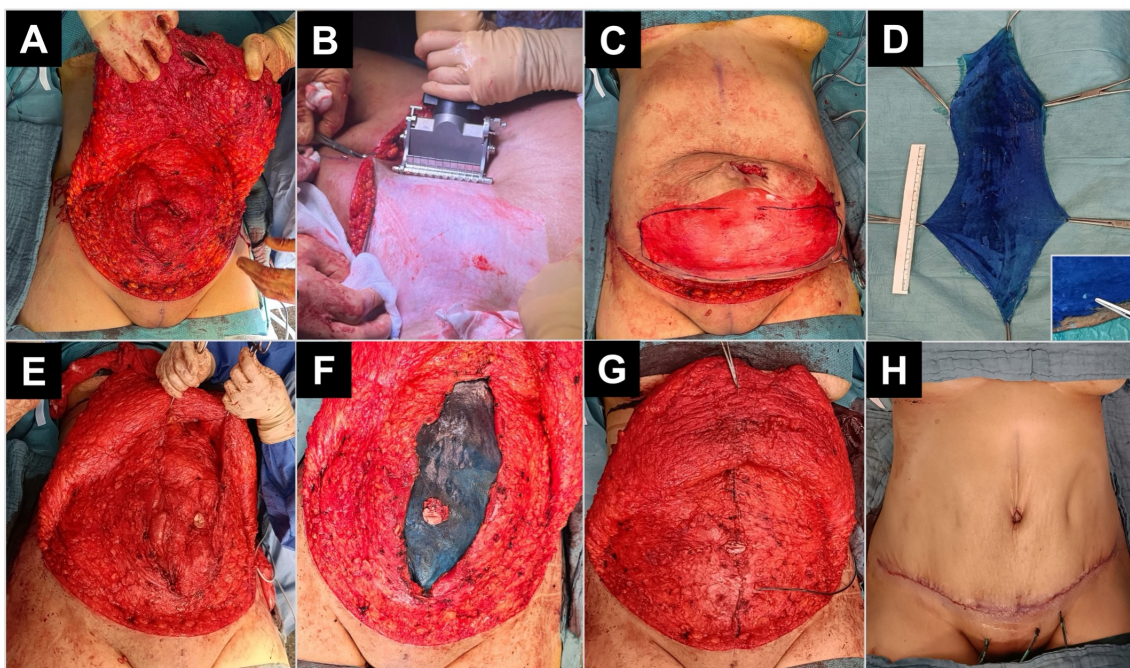


Fig. 1 – Overview of the surgical steps. First, standard approach as for abdominoplasty (A). The skin in excess is de-epithelialized with a dermatome (B) and the necessary dermal flap resected (C). Verification of de-epithelialization with methylene-blue staining (D). Hernia repair following Rives-Stoppa, with closure of the posterior fascia (E), placement of the dermal graft in sublay position (F) and closure of the anterior fascia (G). Finally, reconstruction of the umbilicus and closure over suction drainages (H).

CONCLUSION

Autologous dermis may be used for abdominal wall reconstruction, instead of artificial mesh [2]. This offers attractive alternatives in case of infection or in young patients, avoiding foreign body implantation. Considering the necessary size of the graft, this is best combined with abdominoplasty. Results from small series and individual cases are promising [2].

REFERENCES

- [1] Hernández-Granados et al, BJS 2021
- [2] Martis & Damjanovich, Hernia 2016